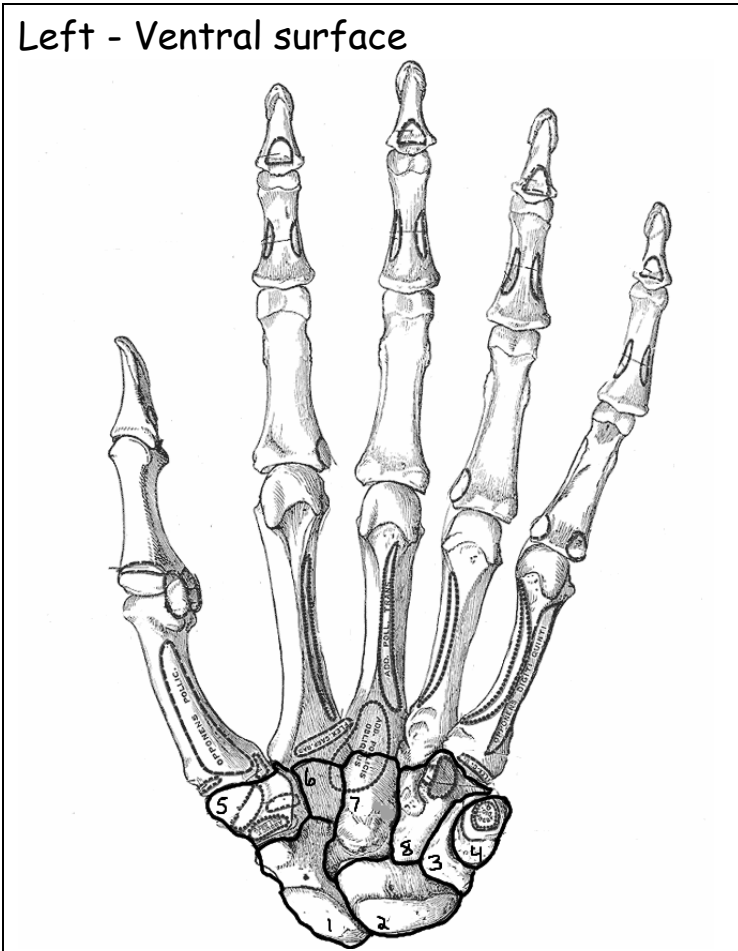


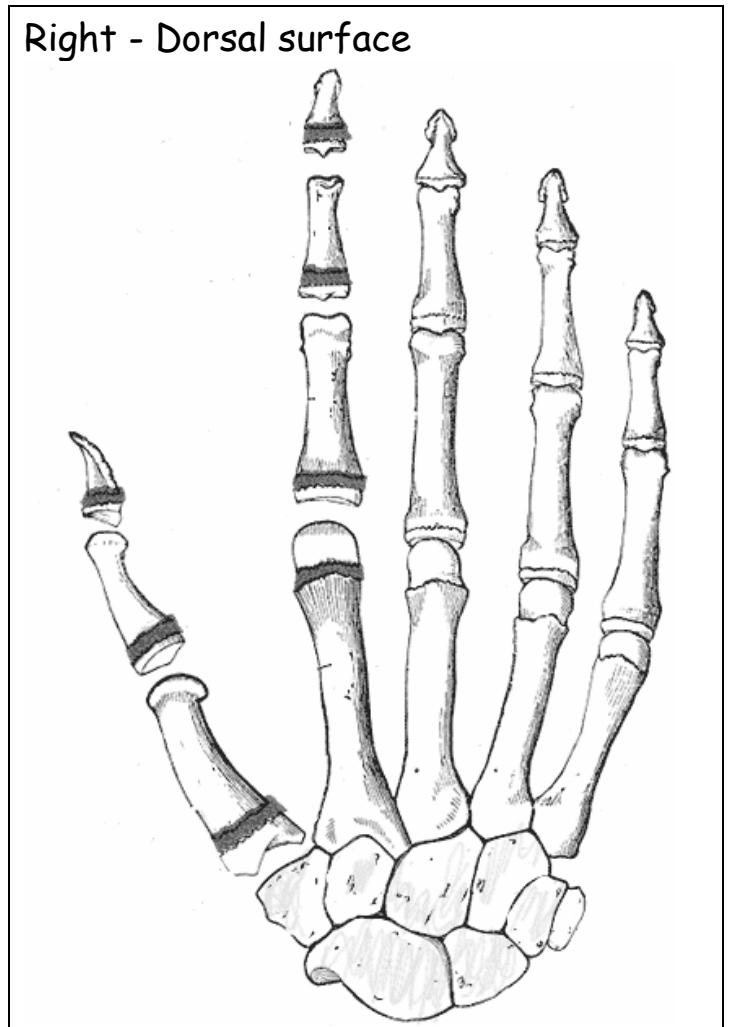


Hand

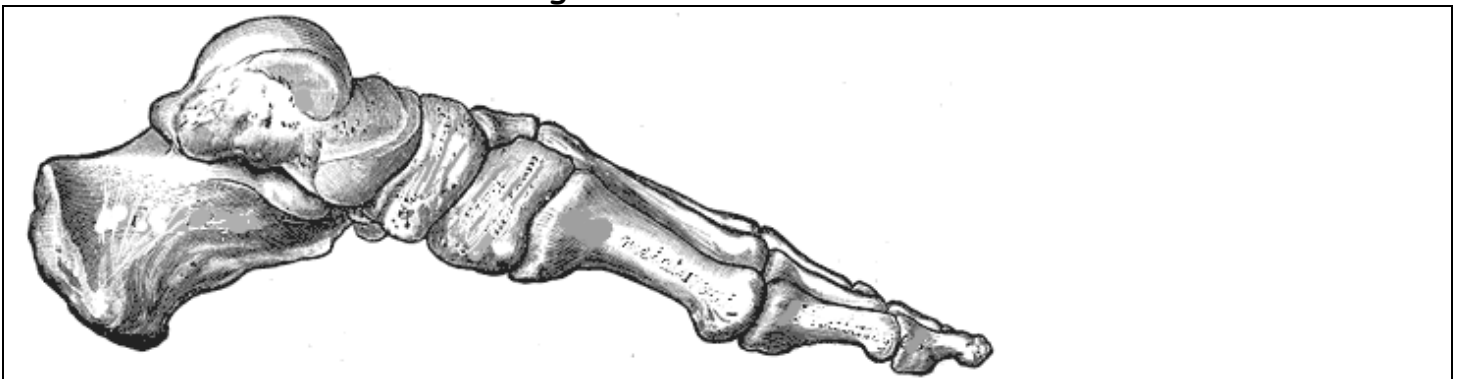Left - Ventral surface



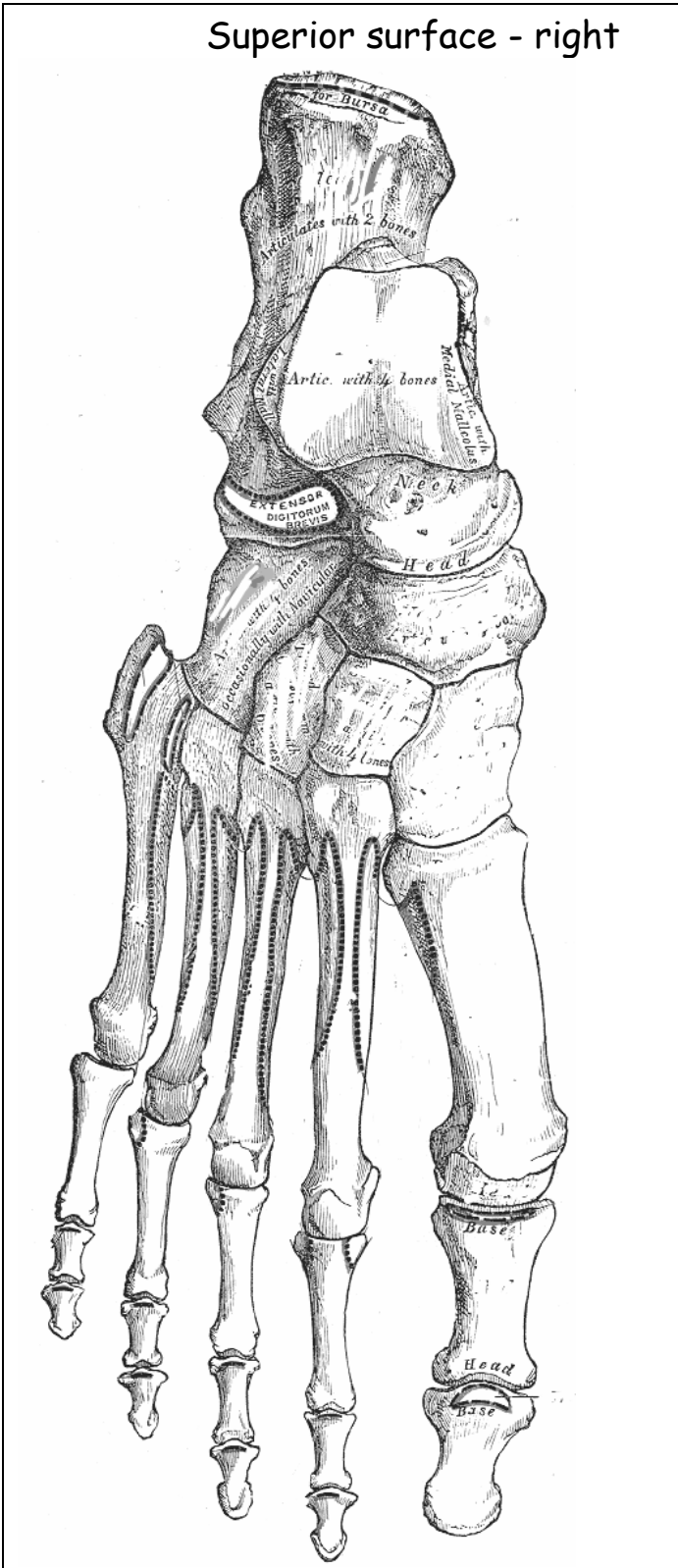
Right - Dorsal surface



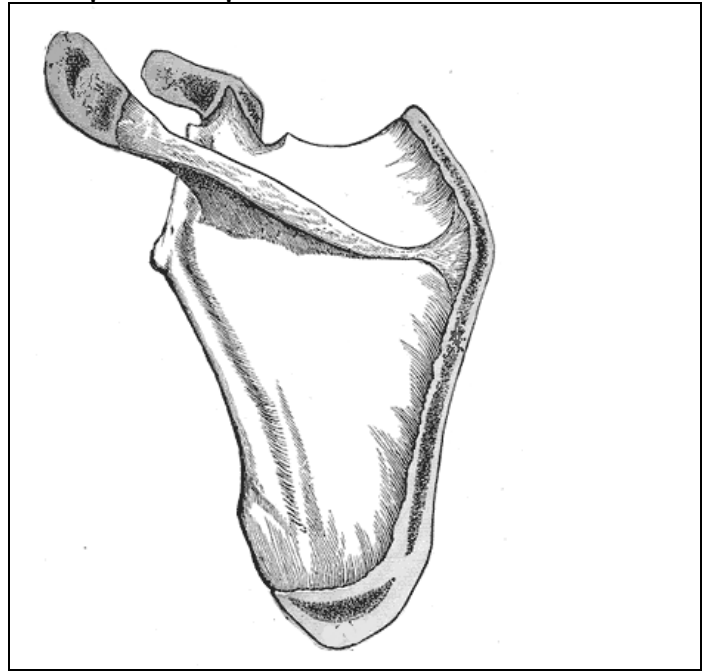
Foot and ankle Medial view- right



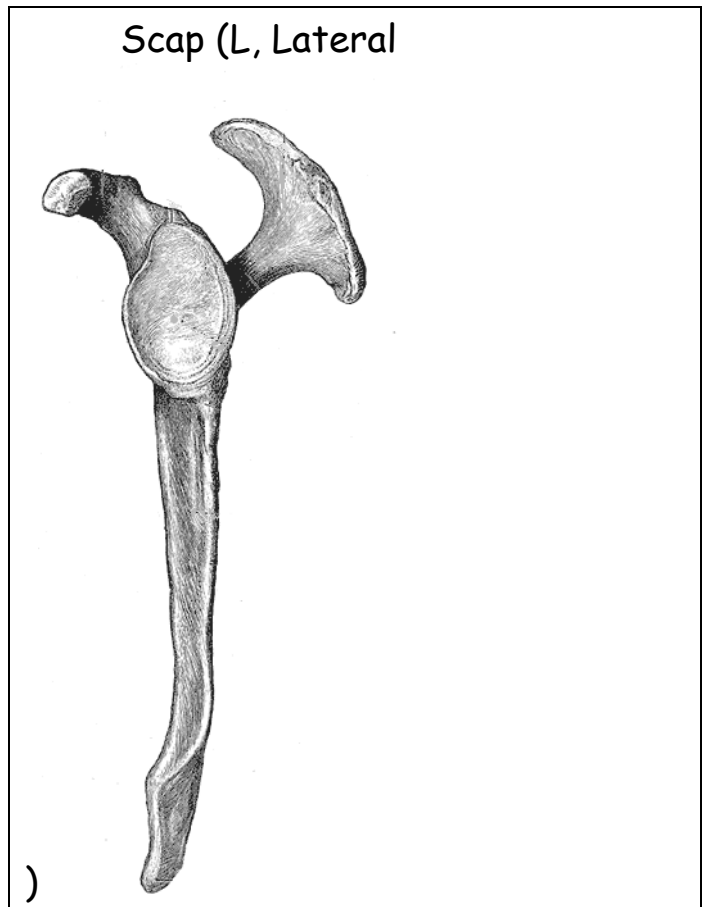
Superior surface - right

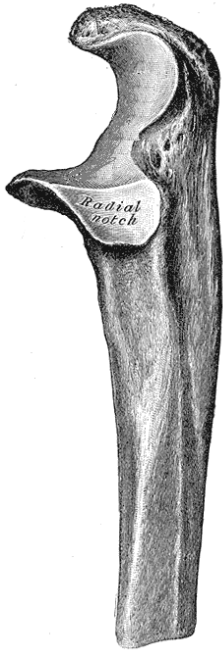


Scapula (L, posterior)

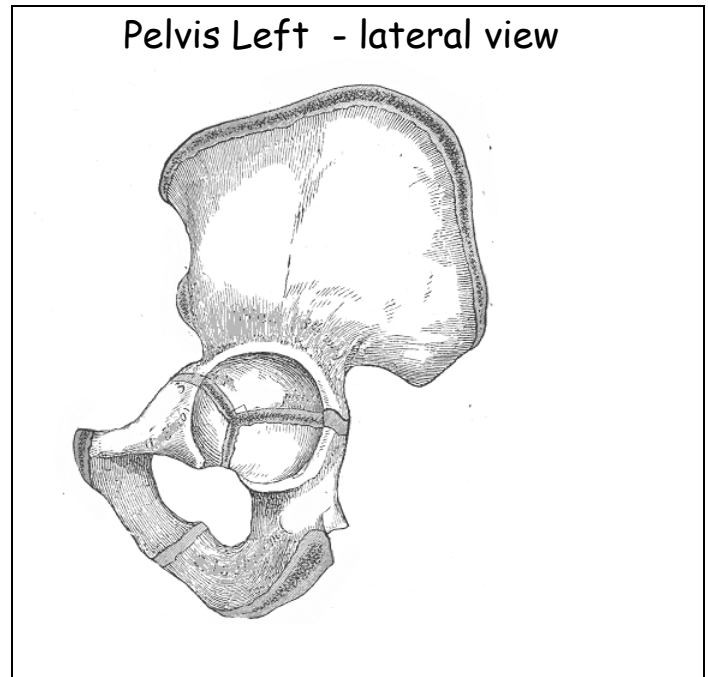


Scap (L, Lateral)

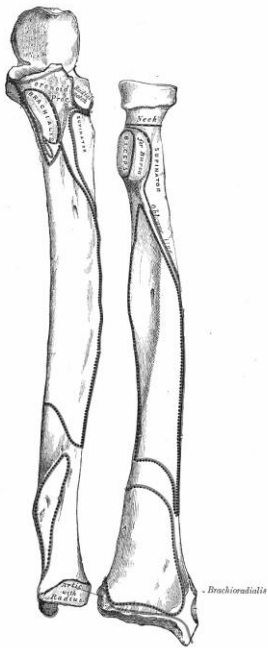




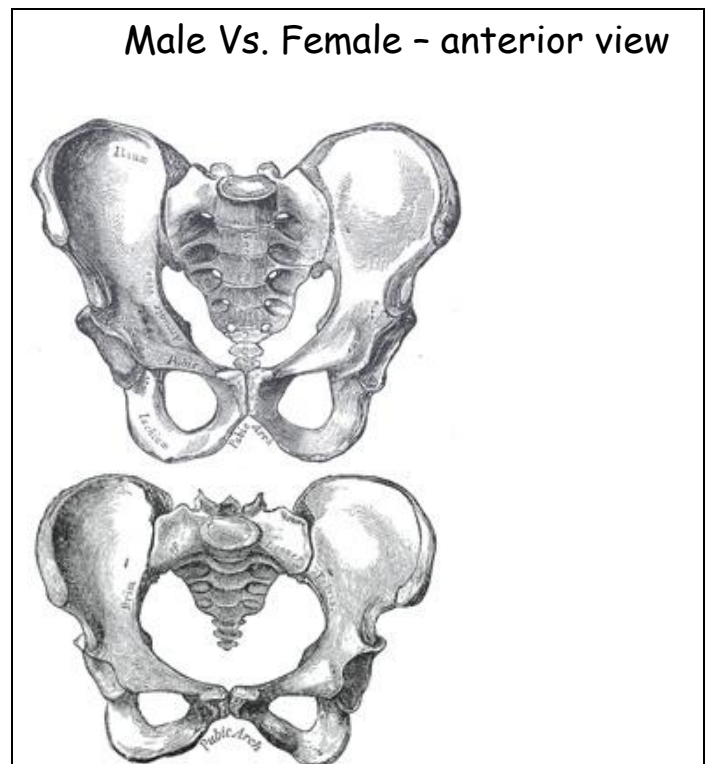
Ulna (lateral)



Pelvis Left - lateral view



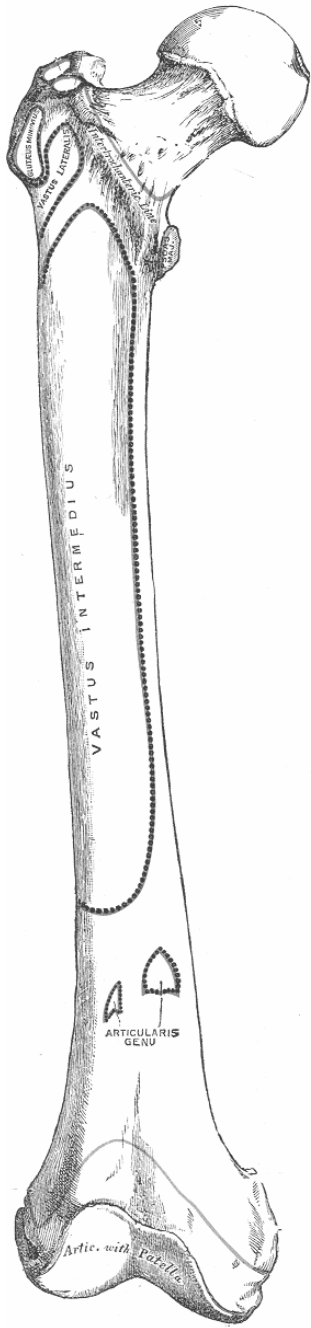
Radius & Ulna (L anterior)



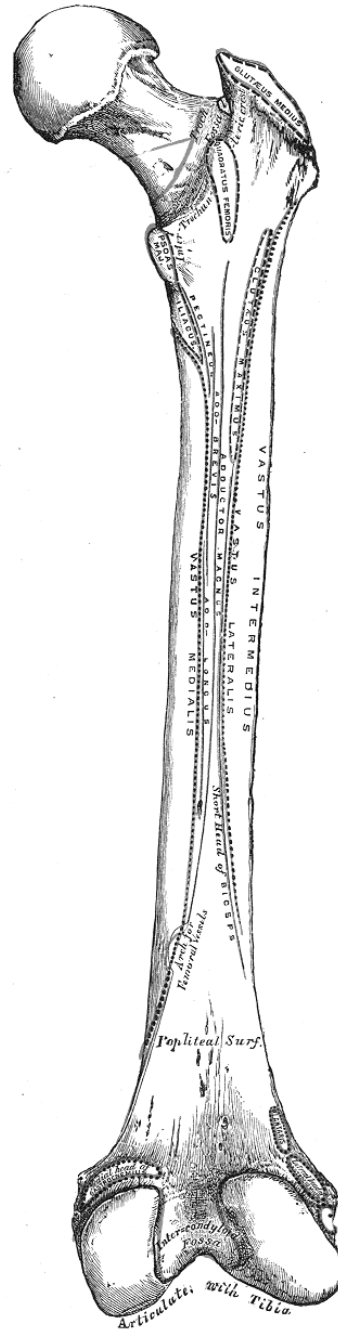
Male Vs. Female - anterior view

Femur


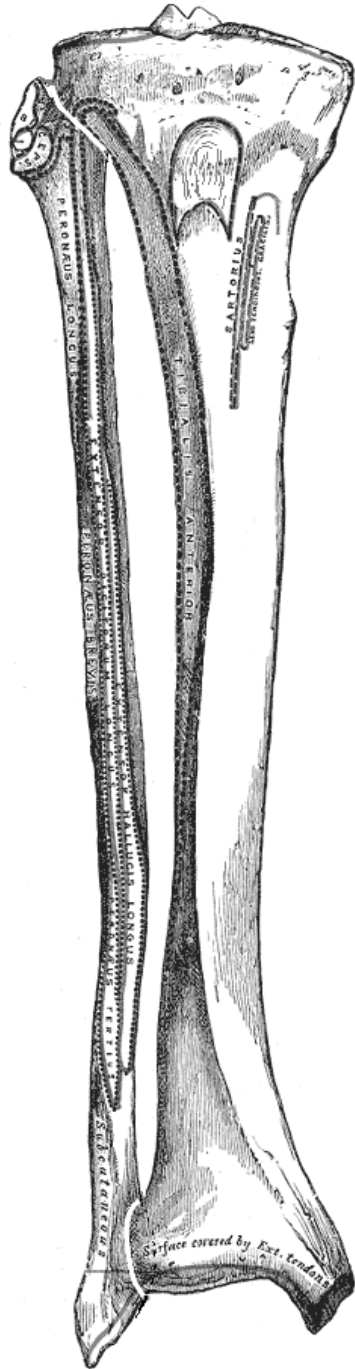
R Anterior



R Posterior



Tibia and Fibula - R Anterior



Fibula - R, lateral