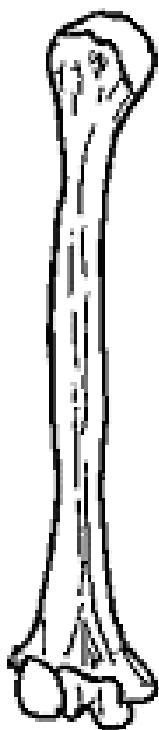


Clavicle (right, superior surface)

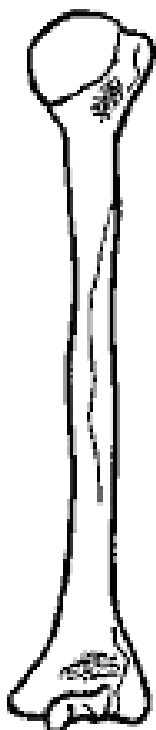


Humerus – right

Anterior view

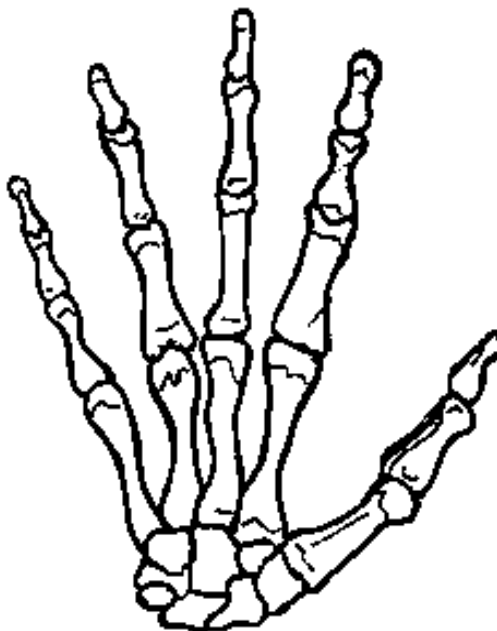


Posterior view

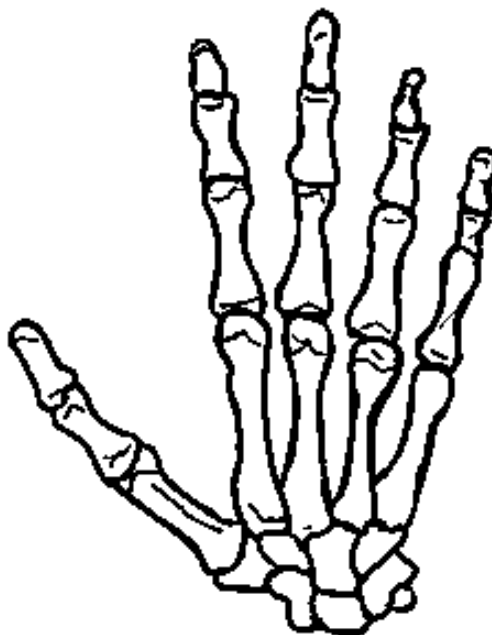


Hand – right

Ventral surface




Dorsal surface

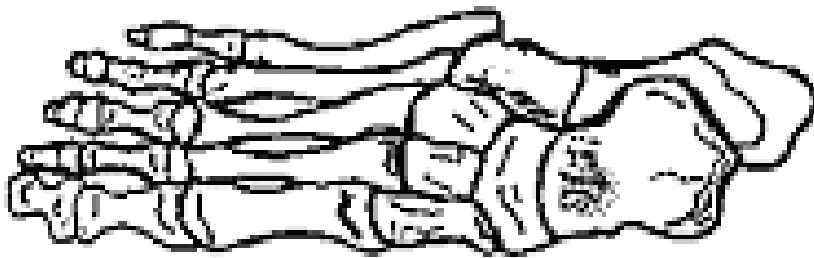


Foot and ankle – right

Medial view

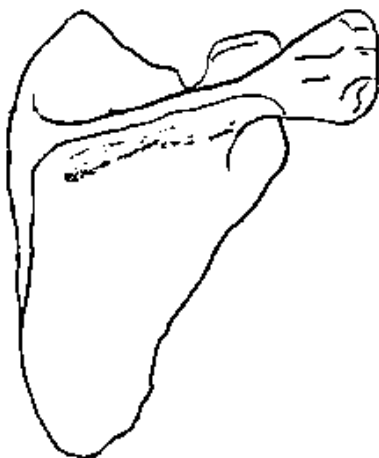


Superior surface

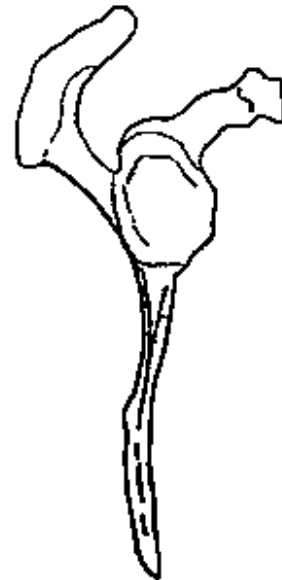


Scapula – right


Posterior surface




Lateral



Radius and Ulna
Anterior

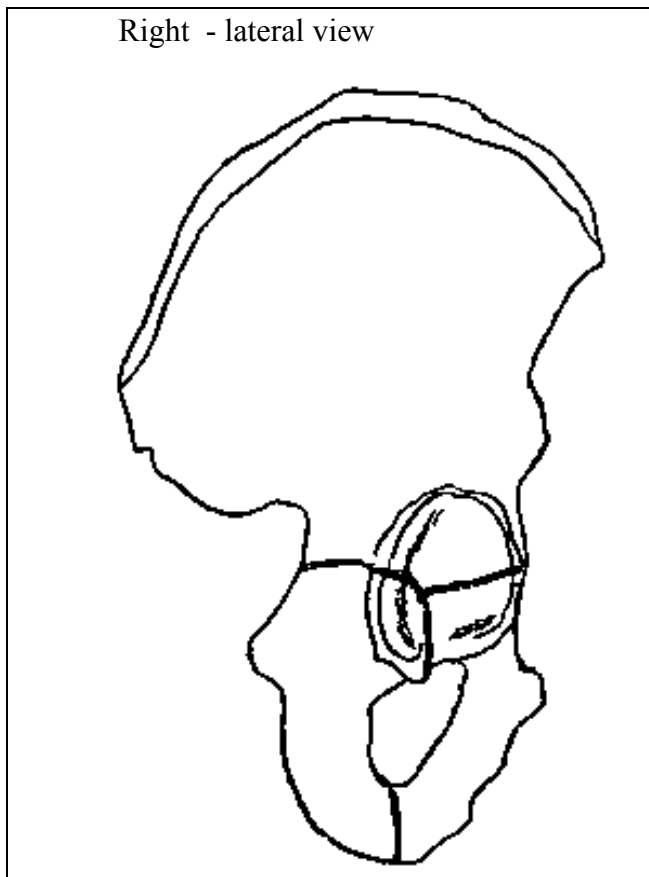


Posterior

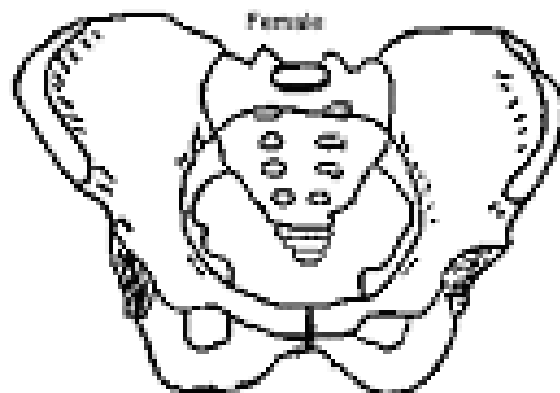
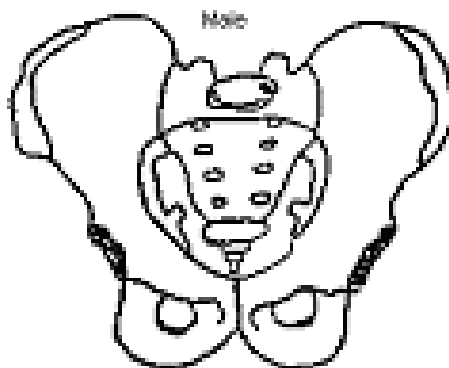


Pelvis

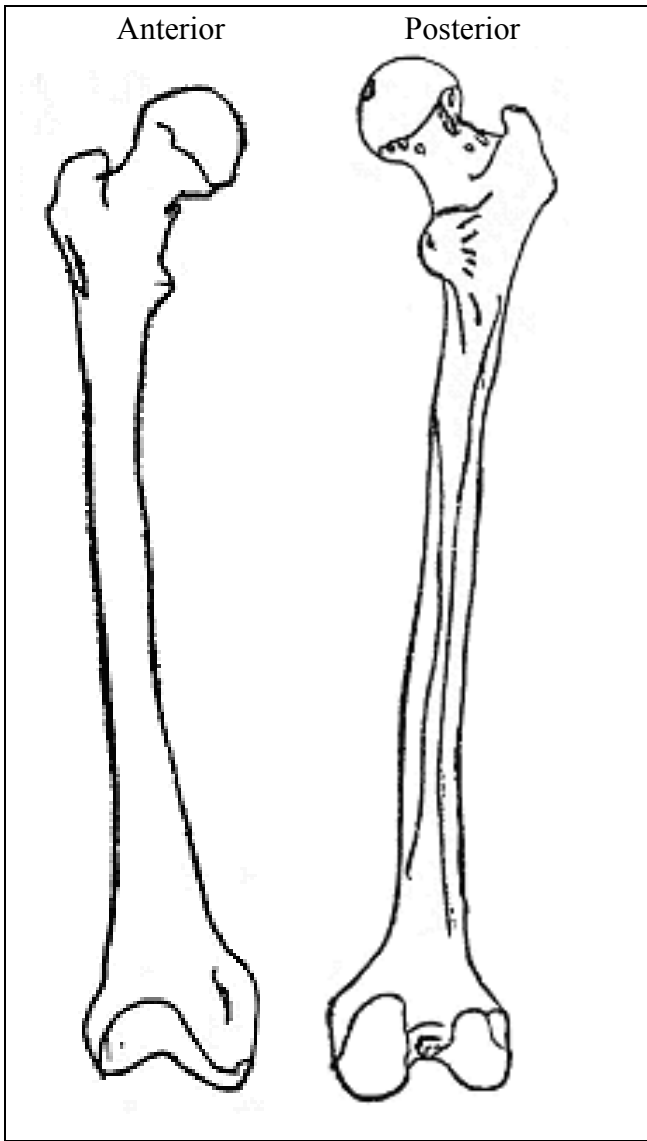
Right - lateral view



Male Vs. Female – anterior view



Femur



Tibia and Fibula
Anterior

